P#15

Abstract Title:	**Minimally Invasive ECCO2R Using The Cardiohelp Permits Reductions In Ventilator Settings In Swine With Smoke Inhalation And Burns**
Author and Co-authors:	Brendan Beely, BS, RRT, Kyle Sieck, BS, Daniel Wendorff, BS, Teryn Roberts, PhD, George Harea, BS, John Jones, BS, Ji Lee, Isabella Garcia, BS, R. Patrick Willis, BS, Jae Choi, PhD, DVSc, The Geneva Foundation, San Antonio, TX Andriy I. Batchinsky, MD, United States Army Institute of Surgical Research, San Antonio, TX
Objective:	1) Describe benefit of minimally invasive CO2 removal in the treatment of smoke inhalation and burns.
Abstract:	**Introduction**: Acute Respiratory Distress Syndrome (ARDS) is characterized by hypoxia, radiographic evidence of bilateral lung consolidation, non-cardiogenic pulmonary edema and carries 30-40% mortality. The standard treatment for ARDS is mechanical ventilation (MV), which is by itself injurious and exacerbates lung injury necessitating a search for novel lung sparing critical care solutions. Reductions of MV settings can reduce mortality due to ventilator induced lung injury (VILI), but can also cause CO2 retention and hypoxemia. Extracorporeal carbon dioxide removal (ECCO2R) is a form of minimally-invasive extracorporeal life support (ECLS) that removes CO2; reduces work of breathing in spontaneously breathing patients with lung impairment and prevents intubation or facilitates earlier extubation in critically ill. ECCO2R combats hypercarbia, permits reductions in ventilator settings, normalizes pH and reduces the risk of ventilator-induced lung injury. We previously demonstrated that ECCO2R using the Hemolung and Xenios sytems reduces minute ventilation in both healthy and anesthetized swine with ARDS. In this study we utilized our established model of smoke inhalation injury and 40% total body surface area burns to investigate the adjunct use of a pediatric ECLS membrane and the mechanical ventilator in management of animals during 72 hours of ICU stay. We hypothesized that minimally invasive ECLS reduces ventilator settings while maintaining normocarbia. **Methods**: Ten anesthetized, female Yorkshire pigs were mechanically ventilated. Baseline ventilator and blood gases were then drawn. The animals then received cooled wood-bark smoke inhalation and 40%

	TBSA flame burn. After injury animals were placed on ECCO2R with an ECLS 2.8 pediatric membrane (Maquet/Getinge Group) with a dual-lumen 19F catheter (Avalon Elite, Maquet/Getinge Group) percutaneously inserted into the right internal jugular vein without fluoroscopic guidance. After initiation of ECCO2R, ventilator settings were reduced according to ARDSNet. Ventilator settings and blood gases were recorded at baseline, post injury, 1 hour after initiation of ECLS, and every 6 hours after ECLS up to 72 hours. Statistics were performed by SAS, Cary, NC. Data is reported as mean ± SEM, significance accepted at $p < 0.05$. **Results**: After the initiation of ECLS, there was a significant reduction in minute ventilation and tidal volume as seen in figure 1 and 2. The arterial CO2 was maintained within normocarbia (figure 3). ECLS flow, RPM's, and sweep gas rates are seen in figures 4, 5, and 6 respectively. **Conclusions**: Minimally invasive ECCO2R allowed for significant reductions in ventilator settings while maintaining normocarbia. The ECCO2R device was maintained at minimal settings and was still able to prevent CO2 retention.

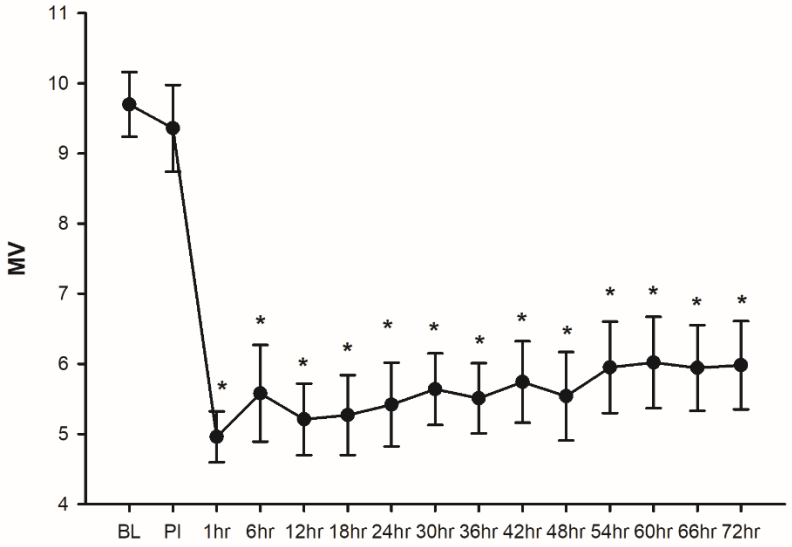

*Figure 1. Minute Ventilation, *significant difference from baseline (p<0.05)*

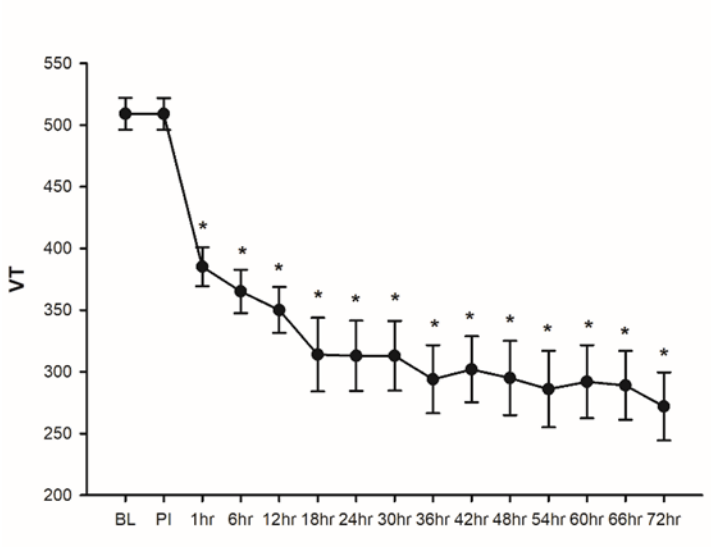

*Figure 2. Tidal Volume, *significant difference from baseline (p<0.05)*

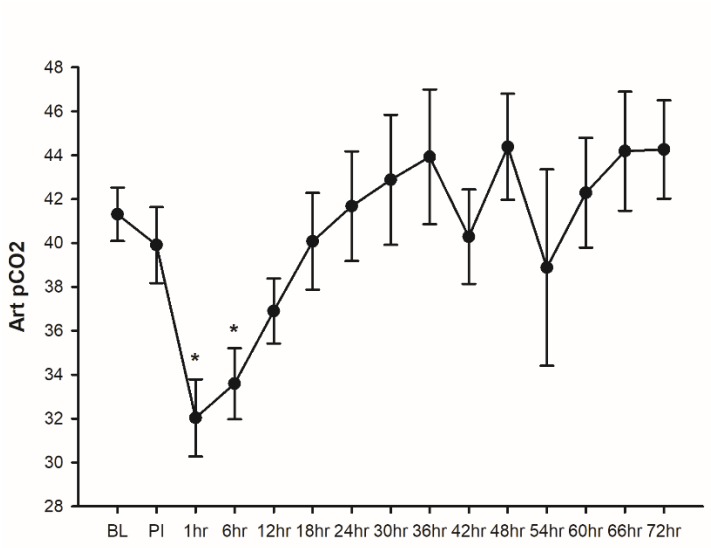

*Figure 3. Arterial pCO_2, *significant difference from baseline (p<0.05)*

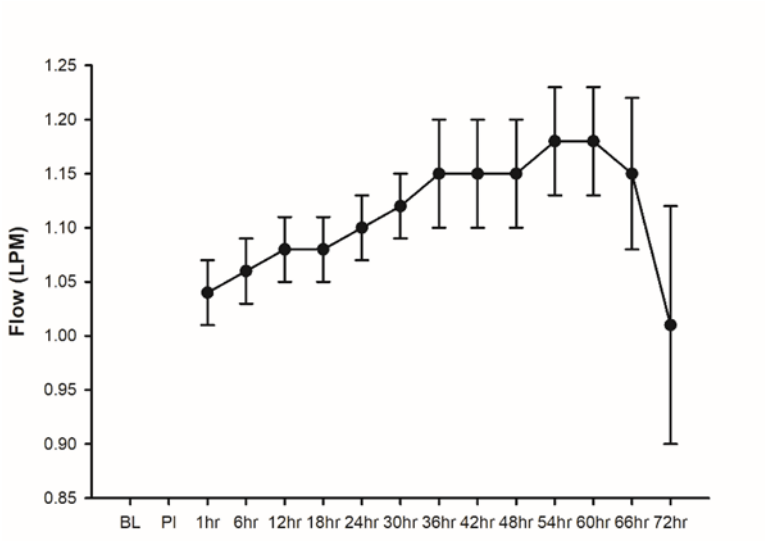

Figure 4. Blood flow through ECLS membrane (LPM)

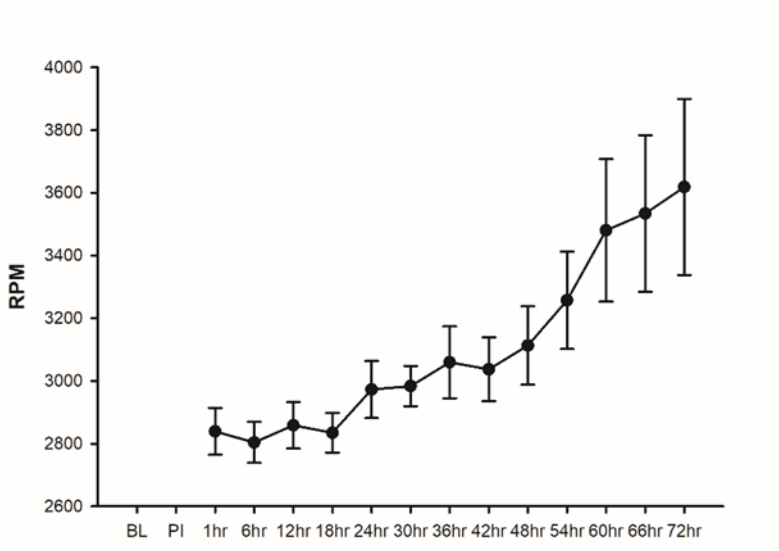

Figure 5. RPM's of ECLS device

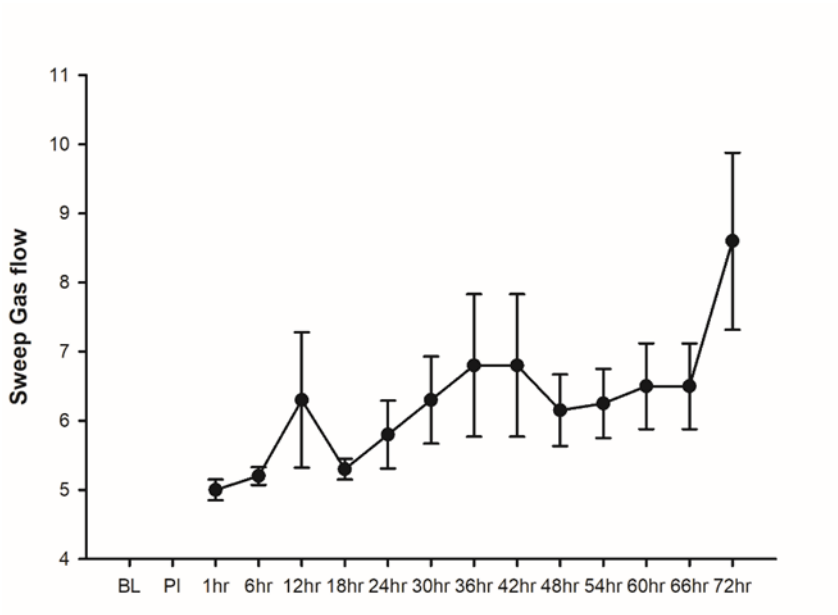

Figure 6. Sweep gas flow (LPM)